

CASE REPORT

Endotracheal intubation with video laryngoscope at semilateral decubitus position: a case report of a pediatric patient with a back stab wound

Maru Kim¹, Kyong-Shil Im², Dae-Hyun Cho¹, Dae-Sang Lee¹, Hangjoo Cho^{1,*}

¹Department of Trauma Surgery, Uijeongbu St. Mary's Hospital, College of Medicine, The Catholic University of Korea, Seoul, Republic of Korea

²Department of Anesthesiology and Pain Medicine, Uijeongbu St. Mary's Hospital, College of Medicine, The Catholic University of Korea, Seoul, Republic of Korea

***Correspondence**

surgeryman@catholic.ac.kr;
10602800@cmcnu.or.kr
(Hangjoo Cho)

Abstract

Background: Endotracheal intubation is routinely performed in a supine position. However, this position might be difficult for some emergent patients. Although several alternative positions have been suggested for adult patients, such studies on pediatric patients are rare. **Case presentation:** We present a case of a female pediatric patient with a pencil stab wound to the back requiring an emergent operation under general endotracheal anesthesia. Placing her in supine position would have been inappropriate because of the protruding pencil. The patient was moved to a semilateral decubitus position for intubation. The endotracheal tube was inserted with a video laryngoscope. Her vital signs and oxygen saturation were stable during operation. The patient was discharged without complications. **Conclusion:** Semilateral intubation in pediatric patients using a video laryngoscope may be feasible under some specific conditions that make it inappropriate to place patients in a supine position.

Keywords

Airway management; Intubation; Pediatric; Position

1. Introduction

Penetrating torso trauma can be lethal to vital organs [1]. It often requires emergent surgery and critical care to control bleeding and manage shock. Airway management is also required during such emergent surgery and critical care. Without a secure airway, disastrous events may occur.

To secure the airway, endotracheal intubation is routinely performed for a patient in a supine position with neck flexion and head extension [2]. However, this position is inappropriate for some patients with trauma, burns, tumors on back, spinal deformity, and so on. These conditions preclude supine positioning. Intubation in a lateral decubitus position is one option. There have been several reports about intubation in a lateral decubitus position for adults [3, 4]. However, reports regarding pediatric patients are rare. This article reports a case of a pediatric patient with an impaled pencil in the back requiring an emergent operation under general endotracheal anesthesia. The process of endotracheal intubation in a semilateral decubitus position is presented via a video.

2. Case report

A 10-year-old female visited the regional trauma center after a slipping incident. A 15 cm pencil penetrated her back and impacted the right flank (Fig. 1). She was in a state of panic with complaint of severe pain. She showed normal vital signs. Her past history and laboratory findings were unremarkable.

To determine the location of the foreign body and internal damage, she was examined with computed tomography (CT). CT images revealed that internal organs were not injured and that the pencil was wedged outside of the rib cage (Fig. 2).

An operation under general endotracheal anesthesia was performed for the following reasons. The pencil impaled the patient tightly, making it difficult to remove the pencil because of severe pain. Proper treatment including bleeding control, massive irrigation, and wound management would have been required after extracting the pencil. Authors thought that the area requiring local anesthesia might be wide and deep that could lead to lidocaine overdose. Additionally, the patient was in panic, needing sedation during the procedure. Therefore, it would have been difficult to remove it under local anesthesia.

Placing her in supine position would have been inappropriate because the protruding pencil impaled her back. She could only pose in lateral or supine position by herself. Therefore, pre-oxygenation was started with the patient in left lateral decubitus position. Rapid sequence intubation with ketamine 10 mg, propofol 50 mg, and succinylcholine 40 mg was performed initially. After oxygenation, the patient was moved to a semilateral decubitus position, being careful not to aggravate the injury in her back. A physician held her and kept her in that position. The endotracheal tube was inserted with a C-MAC video laryngoscope (Karl Storz SE & Co. KG, Tuttlingen, Germany). A full professor of anesthesiology inserted the tube. Although she had no prior experience in

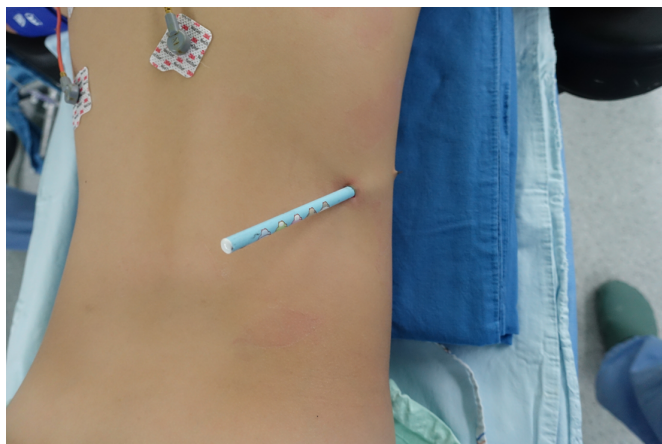

FIGURE 1. A-10-year old girl with a pencil stab wound in the back.

lateral intubation, she inserted the tube successfully on the first attempt (Supplemental Digital Content, Video 1).

After fixation of the tube, the patient was placed in prone position and the planned operation was conducted. The pencil was extracted. Minor bleeding was controlled via ligation and electrocauterization. The pencil's lead broke while it impaled the patient. As a result, tiny particles from the lead had dispersed around tissues, making it difficult to extract particles. The area surrounding the dispersed pencil lead was excised. After massive irrigation, an open drain was inserted in the wound. Second generation cephalosporin was used during admission. The drain was removed at post-operative day (POD) four. Although there had been massive irrigation during operation, the wound was not closed because it was dirty. After the operation, the patient was discharged from the hospital at POD five without complications. The patient showed no complication at out-patient clinic during follow-up. Parent of the patient provided written informed consent for publication of this case. Our Institutional Review Board approved this report (UC20ZASI0058).

3. Discussion

A penetrating object is recommended to be left *in situ*. Extraction should be performed in an operating room or a place where definite management is possible for bleeding and other injuries [5–7]. Impaled object could facilitate identification of an injured organ(s) and prevent overlooking an injury or injuries. It could enable a tamponade effect and prevent bleeding from a vessel or spillage of bowel contents.

Besides an impaled object, many conditions might preclude supine intubation, including lacerations or burn wounds on the back, severe scoliosis, and tumor on the back. These patients cannot be placed in a supine position. They may experience position-related problems during the intubation process. Several alternative intubation methods have been reported. Sawhney *et al.* [8] have reported a patient with a massive thoracoabdominal impalement. An anesthetist on a foot stool inserted a tube in the patient who was in a semi-reclined position. Tantry *et al.* [9] have reported the intubation for a patient with a penetrating injury on two parallel tables. A

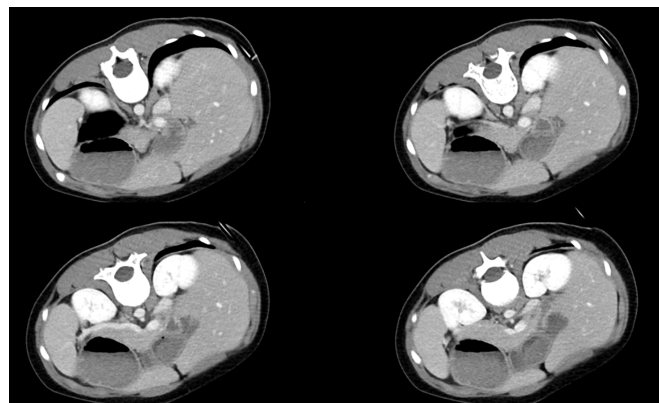


FIGURE 2. CT scans showing the location of the pencil.

patient has also been intubated while in a prone position with laryngeal mask airway [10].

However, a major alternative method is intubation in a lateral decubitus position. Randomized controlled trials have analyzed intubation in a lateral decubitus position [3, 4], reporting that intubation in a lateral decubitus position with a video laryngoscope and a flexible bronchoscope is feasible, effective, and time-saving. Van Zundert *et al.* [11] have also recommend the use of a video laryngoscope in non-standard positions. Additionally, a randomized study has reported that using a video laryngoscope in a sitting or prone position can lead to faster intubation than using a direct laryngoscope [12]. Typical position for intubation is a sniffing position which is also known as supine with neck flexion and head extension [2]. It helps alignment of oral, pharyngeal, and tracheal axes necessary for intubation with laryngoscopy. Video laryngoscope could visualize vocal cord and enable intubation without such alignment. The authors also used a video laryngoscope in this case and accomplished intubation successfully.

Applying a laryngeal mask airway in a lateral decubitus position is another alternative method [13]. Using a laryngeal mask airway has shown better success rate with less time than intubation with a direct laryngoscope in a lateral position [14].

Literature regarding intubation of pediatric patients is scarce. One letter has stated that lateral intubation in pediatric patients is an effective technique in certain cases [15]. Additionally, a randomized trial with child manikin analyzing a semiprone position has been reported [16]. There have been studies using a video laryngoscope that facilitates a lateral intubation in neonates and infants [17–19]. These studies have analyzed non-emergent intubation in infants and neonates. Here, the authors report a rare case of a pediatric intubation with a video laryngoscope in a semilateral decubitus position. The intubation process was successful without complications. This report is unique in that it shows the intubation process with a supplemental digital content.

In conclusion, the authors report a case of a pediatric patient intubated in a semilateral decubitus position. Using a video laryngoscope, the intubation was successful and the patient was treated well. This case report suggests that semilateral intubation using a video laryngoscope may be feasible in pediatric patients under some specific conditions that make it impossible to place patients in a supine position. Thus, emer-

gency physicians, anesthesiologists, trauma surgeons, burn surgeons, pediatricians, intensivists, and other related physicians might consider this method as a proper alternative for some patients. Further study is needed to analyze intubation in pediatric patients in non-supine positions.

ETHICS APPROVAL AND CONSENT TO PARTICIPATE

The parent of the patient provided written informed consent for publication of this case. Institutional Review Board of Uijeongbu St. Mary's Hospital approved this research (UC20ZASI0058).

AUTHOR'S CONTRIBUTIONS

M. Kim curated the data, wrote the draft, and reviewed the manuscript. K Im curated the data and reviewed the draft. D Cho curated the data and wrote the draft. D Lee reviewed the draft and supervised the study. H Cho designed the study and supervised the study.

ACKNOWLEDGEMENTS

We thank peer reviewers and editors for their opinions and suggestions.

CONFLICT OF INTEREST

The authors have no conflicts of interest relevant to this study to disclose.

SUPPLEMENTARY MATERIAL

Supplementary material associated with this article can be found, in the online version, at [https://oss.signavitae.com/mre-signavitae/article/1326770797887275008/attachment/SV2020081403-Supplemental%20Digital%20Content%20\(Video%201\).mp4](https://oss.signavitae.com/mre-signavitae/article/1326770797887275008/attachment/SV2020081403-Supplemental%20Digital%20Content%20(Video%201).mp4).

SUPPLEMENTAL DIGITAL CONTENT LEGEND

Supplemental Digital Content (Video 1). Endotracheal intubation of the pediatric patient in a lateral decubitus position.

REFERENCES

[1] Bordoni PHC, Santos DMMD, Teixeira JS, Bordoni LS. Deaths from abdominal trauma: analysis of 1888 forensic autopsies. *Revista do Colégio Brasileiro de Cirurgiões*. 2017; 44: 582-595.

[2] Gudivada KK, Jonnavithula N, Pasupuleti SL, Apparasu CP, Ayya SS, Ramachandran G. Comparison of ease of intubation in sniffing position and further neck flexion. *Journal of Anaesthesiology Clinical Pharmacology*. 2017; 33: 342-347.

[3] Li H, Wang W, Lu YP, Wang Y, Chen LH, Lei LP, *et al*. Evaluation of endotracheal intubation with a flexible fiberoptic bronchoscope in lateral

patient positioning: A prospective randomized controlled trial. *Chinese Medical Journal (Engl)*. 2016; 129: 2045-2049.

[4] Jin Y, Ying J, Zhang K, Fang X. Endotracheal intubation under video laryngoscopic guidance during upper gastrointestinal endoscopic surgery in the left lateral position: a randomized controlled trial. *Medicine (Baltimore)*. 2017; 96: e9461.

[5] Dar Rawat J, Goel P, S Kunnur V, Kushwaha B, Kushwaha R. Penetrating injury of pelvis, abdomen and thorax in a child with a trident (trishula). *Association of Pediatric Surgeons of Pakistan Journal of Case Reports*. 2013; 4: 3.

[6] Kaur K, Singhal SK, Bhardwaj M, Kumar P. Penetrating abdomino-thoracic injury with an iron rod: an anaesthetic challenge. *Indian Journal of Anaesthesiology*. 2014; 58: 742-745.

[7] Isenburg S, Jackson N, Karmy-Jones R. Removal of an impaled knife under thoracoscopic guidance. *Canadian Respiratory Journal*. 2008; 15: 39-40.

[8] Sawhney C, D'souza N, Mishra B, Gupta B, Das S. Management of a massive thoracoabdominal impalement: a case report. *Scandinavian Journal of Trauma, Resuscitation and Emergency Medicine*. 2009; 17: 50.

[9] Tantry TP, Kadam D, Shetty P, Adappa KK, Muralishankar B, Shenoy SP. Penetrating abdominal injury in a polytrauma patient: anaesthetic challenges faced. *Journal of Anaesthesiology Clinical Pharmacology*. 2011; 27: 272-274.

[10] Samantaray A. Tracheal intubation in the prone position with an intubating laryngeal mask airway following posterior spine impaled knife injury. *Saudi Journal of Anaesthesia*. 2011; 5: 329-331.

[11] Van Zundert TC, Van Zundert AA. Tracheal intubation of patients in non-standard positions requires training. *Minerva Anestesiologica*. 2013; 79: 679-682.

[12] Gaszyński TM. A comparison of a standard macintosh blade laryngoscope, pentax-AWS videolaryngoscope and intubrite videolaryngoscope for tracheal intubation in manikins in sitting and prone positions: a randomized cross-over study. *Diagnostics (Basel)*. 2020; 10: 603.

[13] Lim JA, Jeong MY, Kim JH. Airway management using laryngeal mask airway (LMA) in a patient in a lateral decubitus position: A case report. *Medicine (Baltimore)*. 2019; 98: e18287.

[14] McCaul CL, Harney D, Ryan M, Moran C, Kavanagh BP, Boylan JF. Airway management in the lateral position: a randomized controlled trial. *Anesthesia and Analgesia*. 2005; 101: 1221-1225.

[15] Khan FA. Tracheal intubation in lateral position in paediatric patients. *Journal of the College of Physicians and Surgeons Pakistan*. 2012; 22: 806.

[16] Fevang E, Haaland K, Roislien J, Bjørshol CA. Semiprone position is superior to supine position for paediatric endotracheal intubation during massive regurgitation, a randomized crossover simulation trial. *BMC Anesthesiology*. 2018; 18: 10.

[17] Salama ER, El Amrousy D. GlideScope® cobalt video laryngoscope versus direct Miller laryngoscope for lateral position-tracheal intubation in neonates with myelodysplasia: a prospective randomized study. *Saudi Journal of Anaesthesia*. 2019; 13: 28-34.

[18] Jain D, Mehta S, Gandhi K, Arora S, Parikh B, Abas M. Comparison of intubation conditions with CMAC Miller videolaryngoscope and conventional Miller laryngoscope in lateral position in infants: a prospective randomized trial. *Paediatric Anaesthesia*. 2018; 28: 226-230.

[19] Nagappa S, Sridhara RB, Kalappa S. Comparing the ease of mask ventilation, laryngoscopy, and intubation in supine and lateral position in infants with meningomyelocele. *Anesthesia, Essays and Researches*. 2019; 13: 204-208.

How to cite this article: Maru Kim, Kyong-Shil Im, Dae-Hyun Cho, Dae-Sang Lee, Hangjoo Cho. Endotracheal intubation with video laryngoscope at semilateral decubitus position: A case report of a pediatric patient with a back stab wound. *Signa Vitae*. 2021;17(1):213-215. doi:10.22514/sv.2020.16.0086.